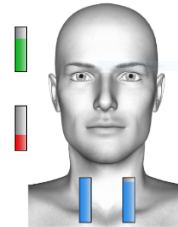
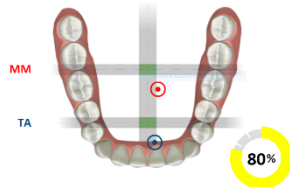
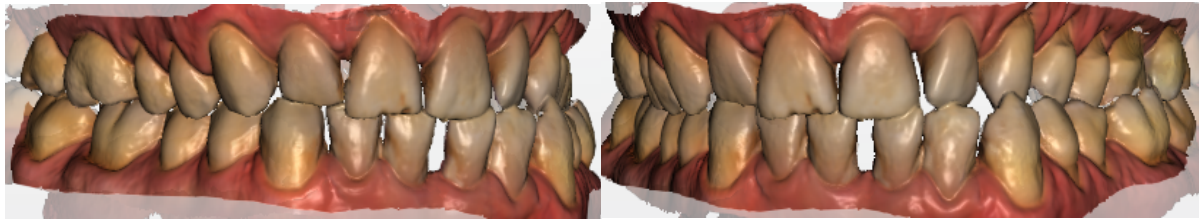


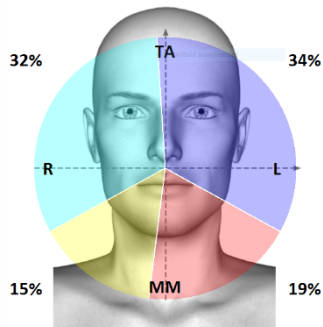
Paz. 1, sesso maschile, 48 anni

Problematiche orali: morso crociato a sx e del 12.



| Indizes | Test     | Normaldaten |
|---------|----------|-------------|
| POC TA  | 87.42% L | 83≤(%)≤100  |
| POC MM  | 82.25% L | 83≤(%)≤100  |
| BAR     | 69.46% A | 90≤(%)≤100  |
| TORS    | 90.33%   | 90≤(%)≤100  |
| IMP     | 82.19%   | 85≤(%)≤115  |

| Indizes | Test     | Normaldaten |
|---------|----------|-------------|
| ASIM    | -5.03%   | -10≤(%)≤10  |
| POC SCM | 79.75% R | 83≤(%)≤100  |
| CL      | 4.13%    | 0≤(%)≤15    |

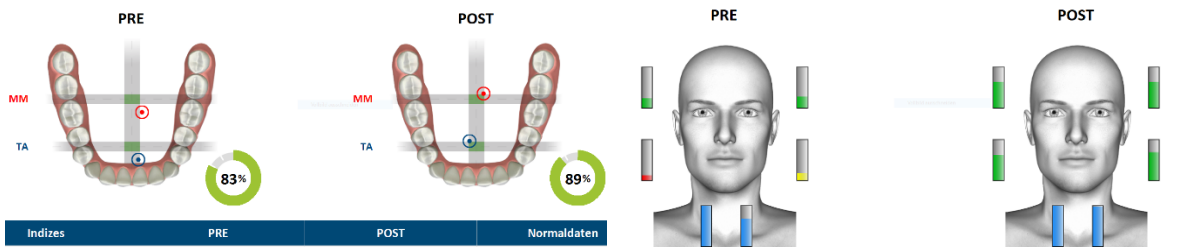


EMG iniziale Teethan®

Problematiche posturali: dismetria bacino dx, dolori rachide cervicale cronici. Frequenti emicranie.

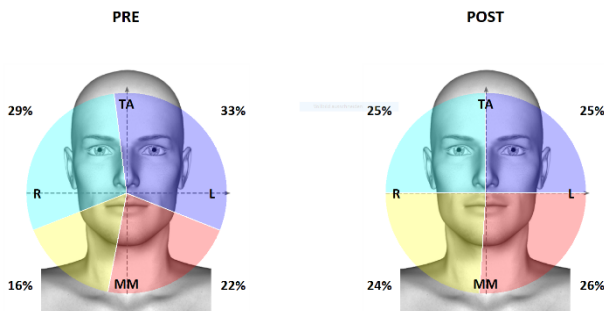
Terapia con bite inferiore e dispositivi Taopatch®.

Bacino nella norma, riduzione antidolorifici e del dolore cervicale.



| Indizes | PRE      | POST     | Normaldaten |
|---------|----------|----------|-------------|
| POC TA  | 87.19% L | 87.24% R | 83≤(%)≤100  |
| POC MM  | 80.63% L | 85.76% L | 83≤(%)≤100  |
| BAR     | 77.19% A | 90.73% P | 90≤(%)≤100  |
| TORS    | 90.86%   | 90.42%   | 90≤(%)≤100  |
| IMP     | 84.03%   | 94.31%   | 85≤(%)≤115  |

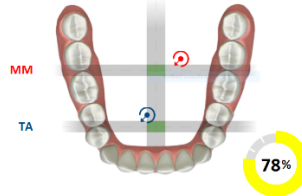
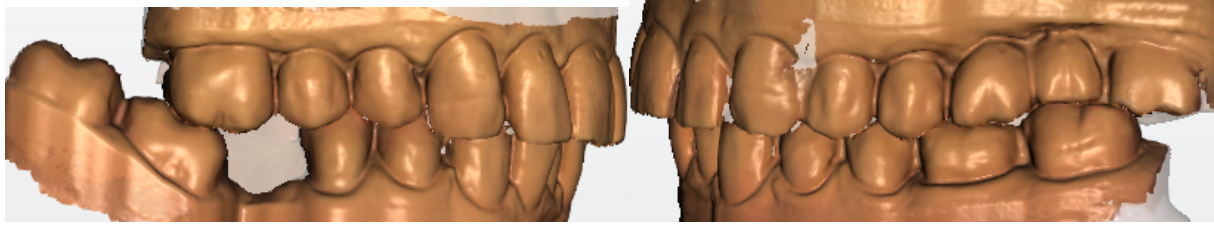
| Indizes | PRE      | POST     | Normaldaten |
|---------|----------|----------|-------------|
| ASIM    | -9.78%   | -2.27%   | -10≤(%)≤10  |
| POC SCM | 75.19% R | 83.21% R | 83≤(%)≤100  |
| CL      | 8.59%    | 3.52%    | 0≤(%)≤15    |



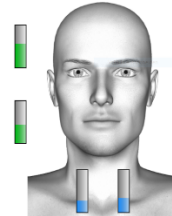
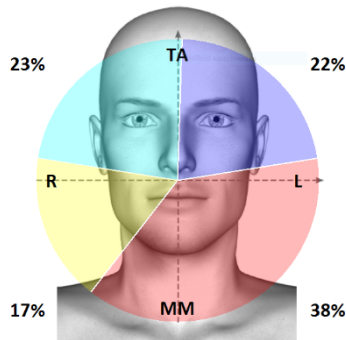
EMG attuale Teethan®

Paz. 2, sesso maschile, 43 anni

Problematiche orali: mancanza del 46, laterodeviiazione dx e click articolare sx.



| Indizes | Test     | Normaldaten |
|---------|----------|-------------|
| POC TA  | 86.29% R | 83≤(%)≤100  |
| POC MM  | 59.39% L | 83≤(%)≤100  |
| BAR     | 83.76% P | 90≤(%)≤100  |
| TORS    | 75.70% R | 90≤(%)≤100  |
| IMP     | 116.64%  | 85≤(%)≤115  |



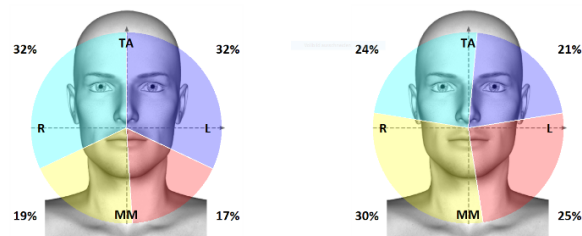
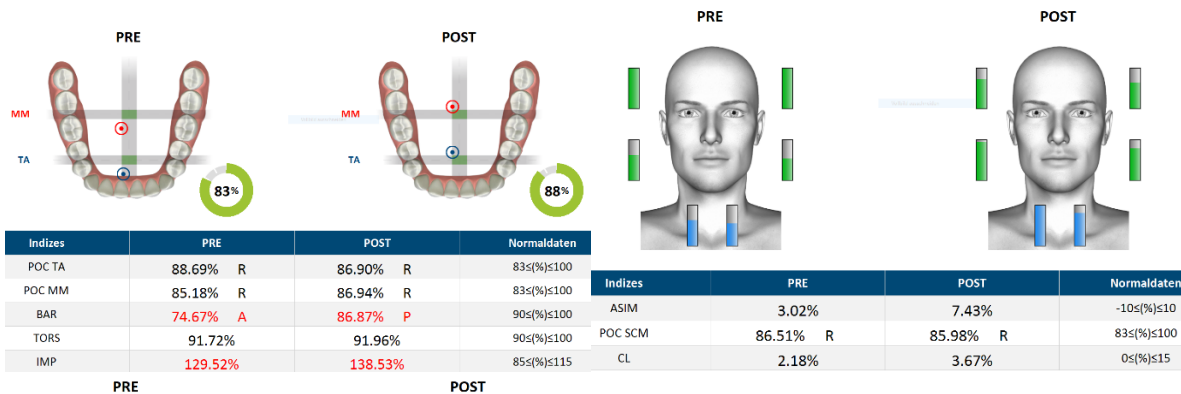
| Indizes | Test     | Normaldaten |
|---------|----------|-------------|
| ASIM    | -20.16%  | -10≤(%)≤10  |
| POC SCM | 81.88% L | 83≤(%)≤100  |
| CL      | 4.91%    | 0≤(%)≤15    |

EMG iniziale Teethan®.

Problematiche posturali: dismetria bacino dx, emicranie ricorrenti e uso costante di antidolorifici.

Terapia con bite superiore e dispositivi Taopatch®.

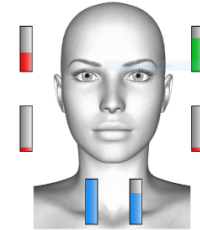
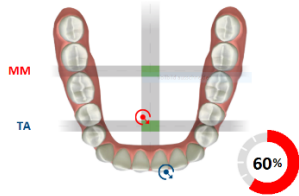
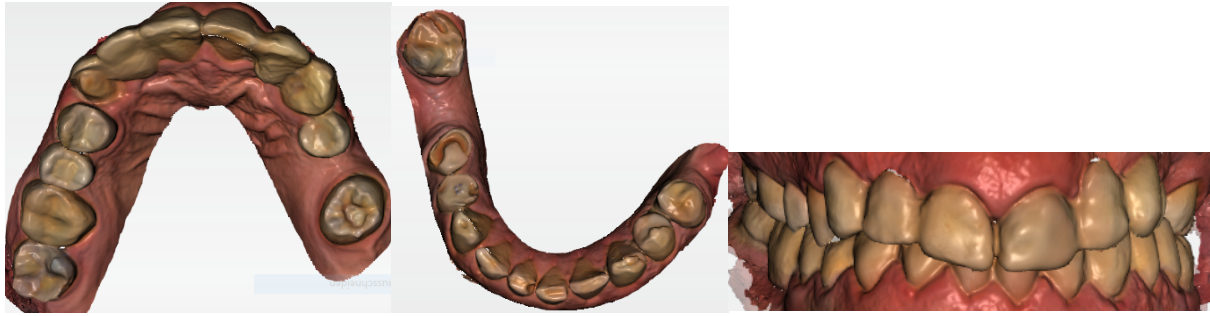
Bacino nella norma, emicranie scomparse, uso farmaci quasi nullo.



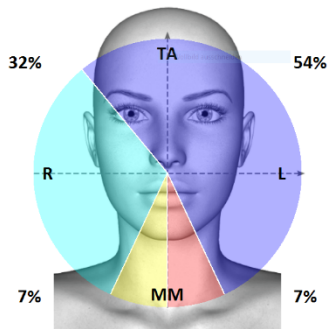
EMG attuale Teethan®

**Paz. 3, sesso femminile, 52 anni**

Problematiche orali: morso profondo, edentulie, click articolare sx, ridotta e dolente apertura.



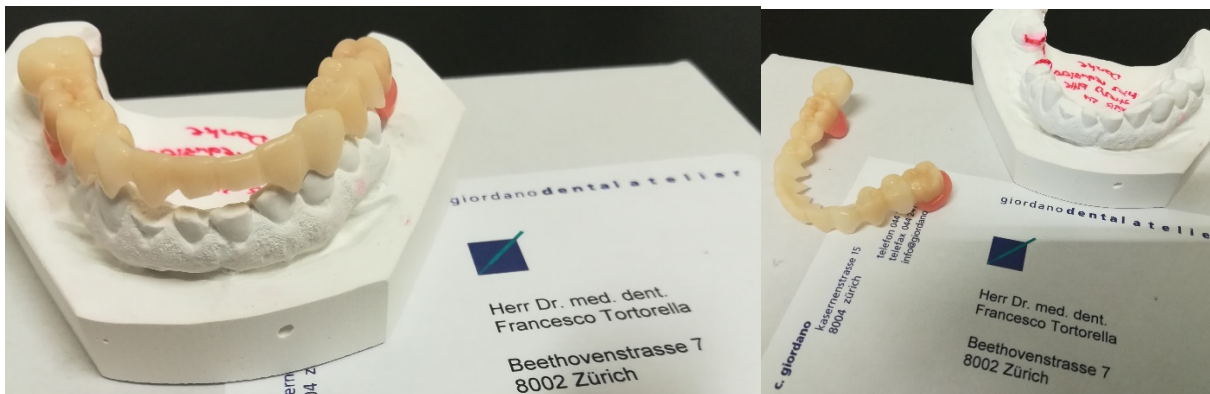| Indizes | Test     | Normaldaten | Indizes | Test     | Normaldaten |
|---------|----------|-------------|---------|----------|-------------|
| POC TA  | 73.27% L | 83≤(%)≤100  | ASIM    | -21.72%  | -10≤(%)≤10  |
| POC MM  | 88.54% R | 83≤(%)≤100  | POC SCM | 77.13% R | 83≤(%)≤100  |
| BAR     | 31.56% A | 90≤(%)≤100  | CL      | 2.53%    | 0≤(%)≤15    |
| TORS    | 76.77% L | 90≤(%)≤100  |         |          |             |
| IMP     | 39.20%   | 85≤(%)≤115  |         |          |             |



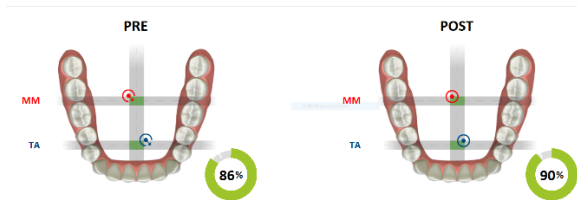
**EMG iniziale Teethan®**

Problematiche posturali: dolori rachide cervicale, dolori avambraccio sx (utilizzo di tutor), utilizzo costante di Voltaren.

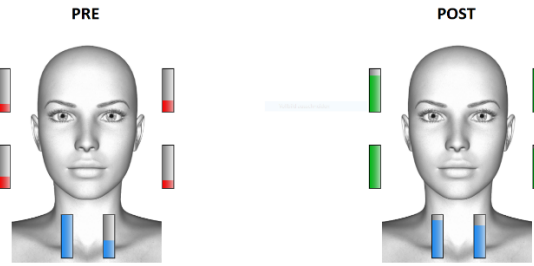
Terapia con bite superiore e tecnologia **Taopatch®**, rialzo totale masticazione con blocco in resina (vedere foto, Laboratorio Giordano).



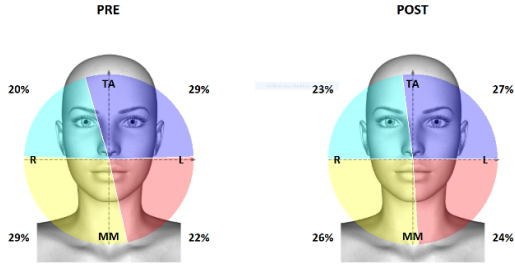
Dolori cervicali ridotti, apertura bocca nella norma e senza dolore. Problemi all'avambraccio scomparsi.



| Indizes | PRE      | POST     | Normaldaten |
|---------|----------|----------|-------------|
| POC TA  | 80.33% L | 86.51% L | 83≤(%)≤100  |
| POC MM  | 83.90% R | 89.73% R | 83≤(%)≤100  |
| BAR     | 91.09% P | 92.11% P | 90≤(%)≤100  |
| TORS    | 83.52% L | 91.07%   | 90≤(%)≤100  |
| IMP     | 46.78%   | 95.59%   | 85≤(%)≤115  |

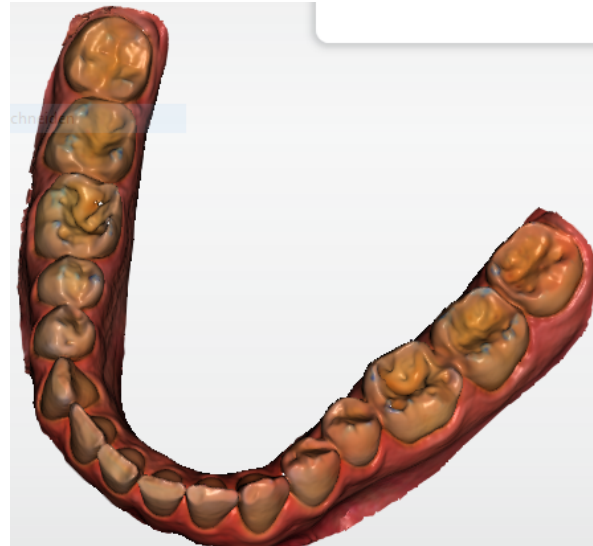
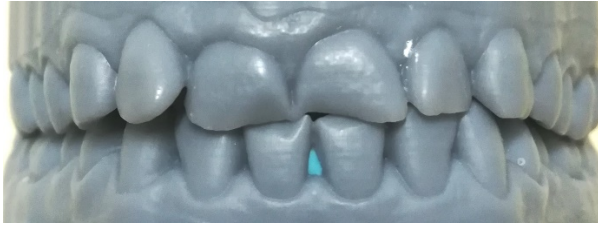
| Indizes | PRE      | POST     | Normaldaten |
|---------|----------|----------|-------------|
| ASIM    | -1.43%   | -2.51%   | -10≤(%)≤10  |
| POC SCM | 59.16% R | 85.36% R | 83≤(%)≤100  |
| CL      | 2.55%    | 2.49%    | 0≤(%)≤15    |



EMG attule Teethan®

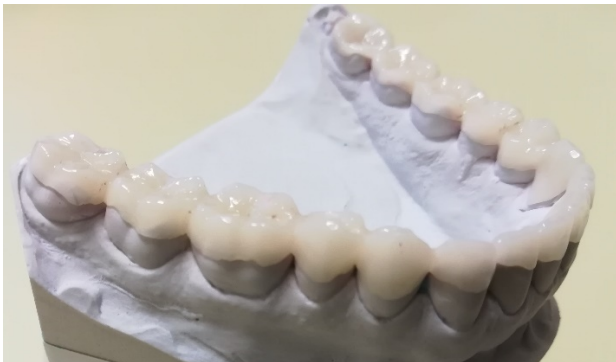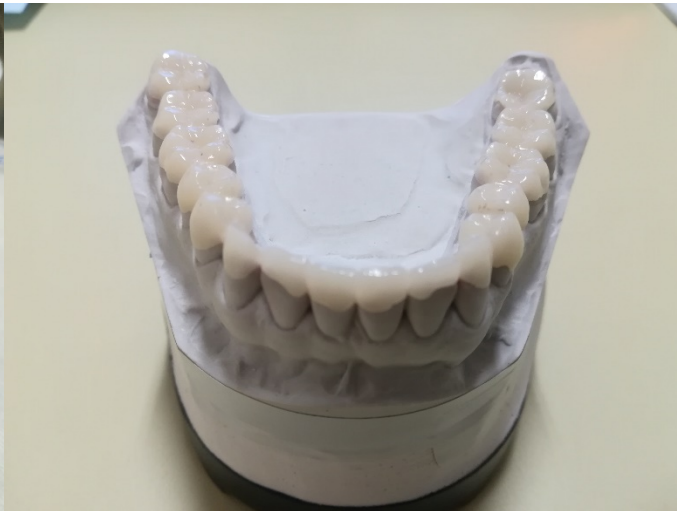Paz. 4, sesso femminile, 43 anni

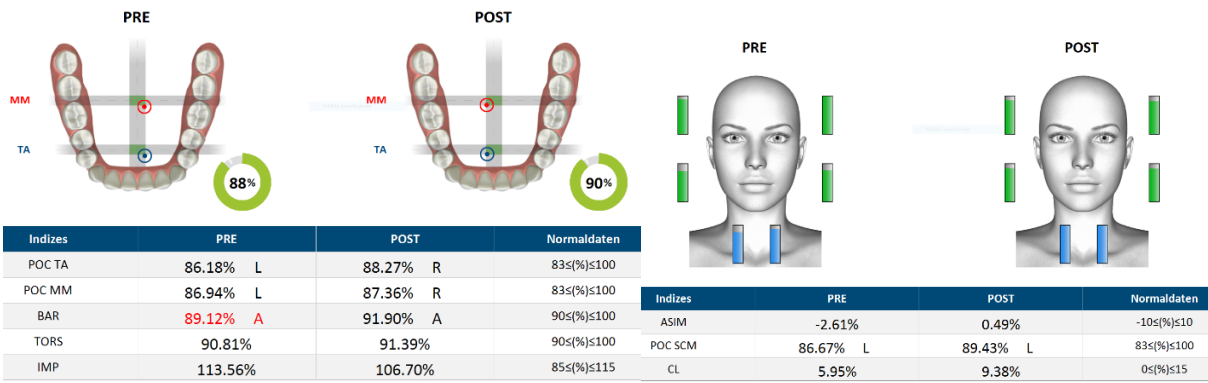


Problematiche orali: morso profondo, erosioni incisali ed occlusali, click articolare sx.

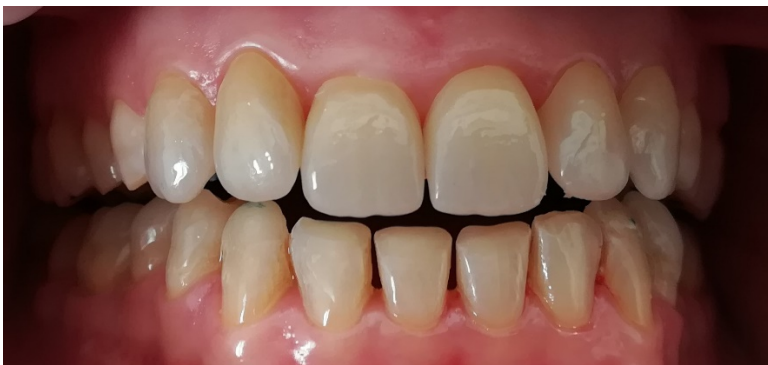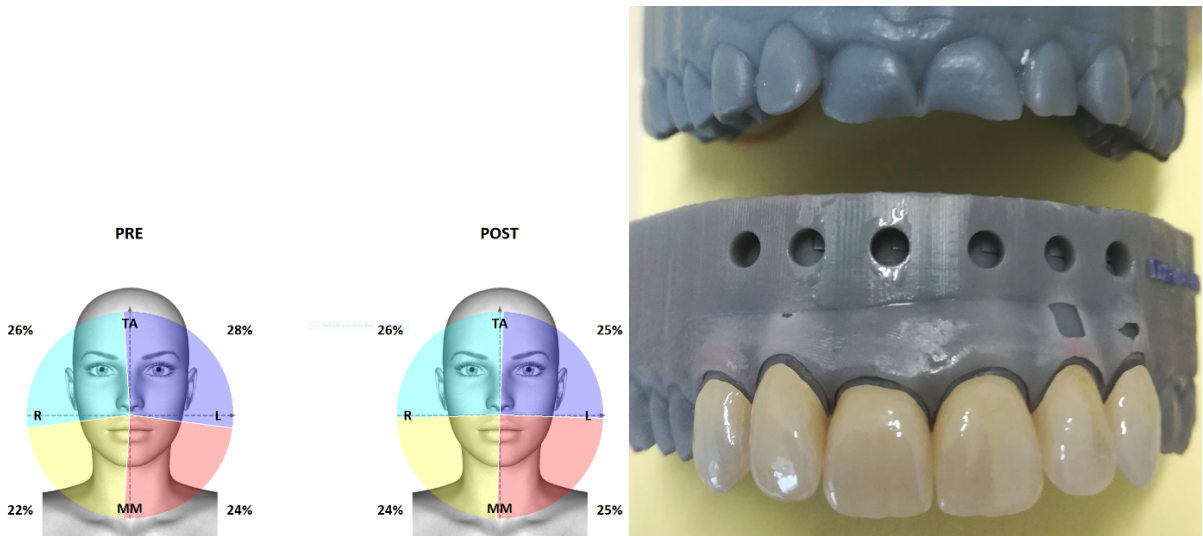
Problematiche posturali: dolori muscolari cervicali, mal di testa.

Terapia con bite superiore e tecnologia Taopatch® (ca. 12 mesi), rialzo masticaione totale inferiore.



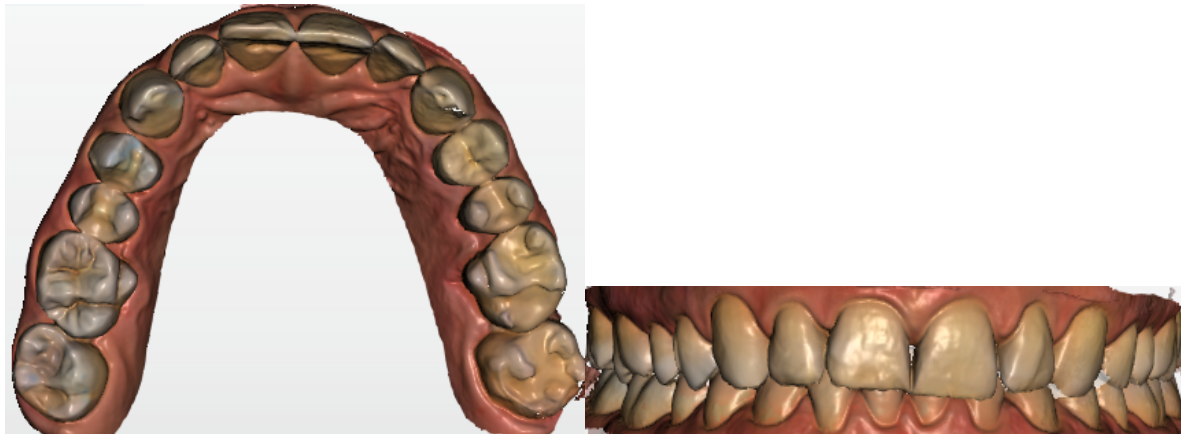


EMG attuale Teethan®

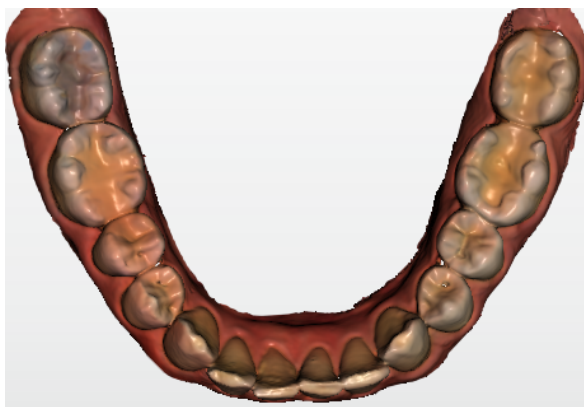


Corone sup. finali.

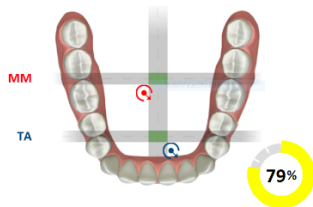
Paz. 5, sesso femminile, 53 anni



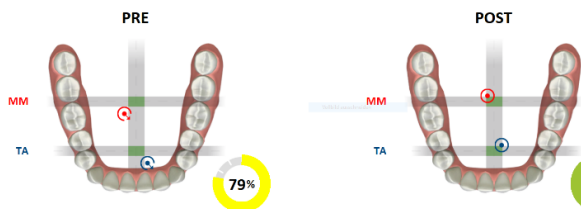
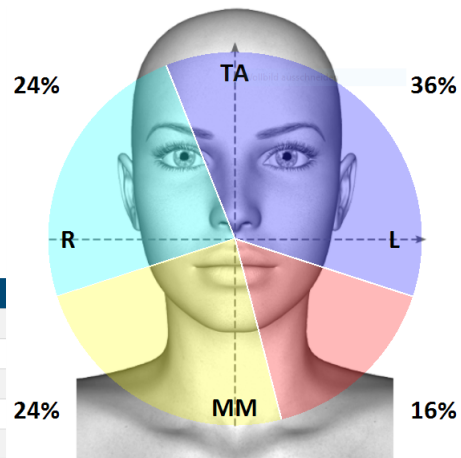
Problematiche orali: bruxista, morso profondo, costanti dolori cervicali, mancanza di ernie cervicali.



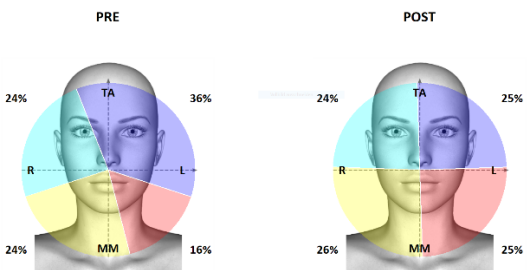
EMG iniziale Teethan®



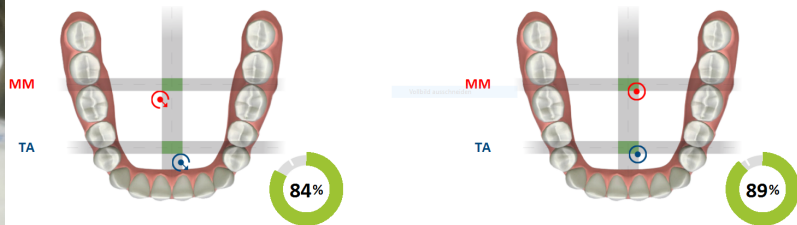
| Indizes | Test     | Normaldaten |
|---------|----------|-------------|
| POC TA  | 78.38% L | 83≤(%)≤100  |
| POC MM  | 78.53% R | 83≤(%)≤100  |
| BAR     | 79.62% A | 90≤(%)≤100  |
| TORS    | 79.33% L | 90≤(%)≤100  |
| IMP     | 106.89%  | 85≤(%)≤115  |



| Indizes | PRE      | POST     | Normaldaten |
|---------|----------|----------|-------------|
| POC TA  | 78.38% L | 86.20% L | 83≤(%)≤100  |
| POC MM  | 78.53% R | 87.81% R | 83≤(%)≤100  |
| BAR     | 79.62% A | 90.45% P | 90≤(%)≤100  |
| TORS    | 79.33% L | 90.15%   | 90≤(%)≤100  |
| IMP     | 106.89%  | 123.62%  | 85≤(%)≤115  |

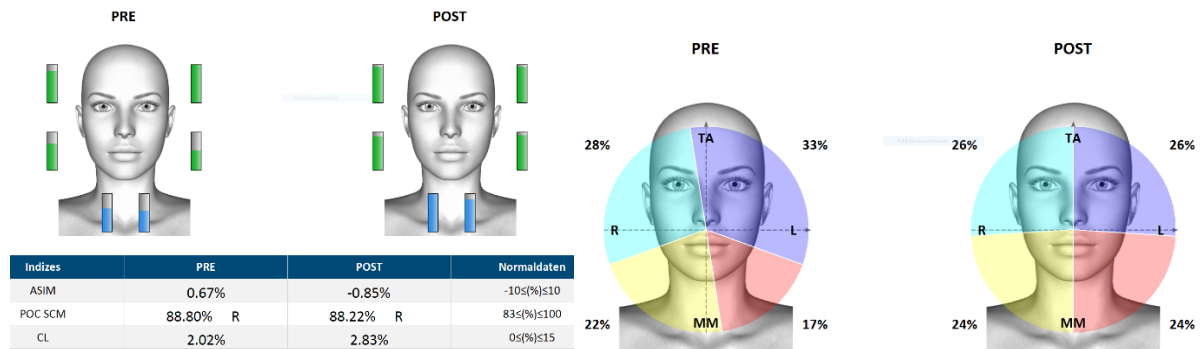


EMG iniziale a sx e con rialzi provvisori della masticazione a dx. Bilanciamento raggiunto.



| Indizes | PRE      | POST     | Normaldaten |
|---------|----------|----------|-------------|
| POC TA  | 86.36% L | 86.11% L | 83≤(%)≤100  |
| POC MM  | 83.61% R | 87.14% L | 83≤(%)≤100  |
| BAR     | 80.02% A | 90.78% A | 90≤(%)≤100  |
| TORS    | 87.68% L | 90.32%   | 90≤(%)≤100  |
| IMP     | 116.86%  | 126.36%  | 85≤(%)≤115  |

La paziente utilizza il bite con tecnologia Taopatch® e i relativi protocolli.



EMG attuale Teethan®



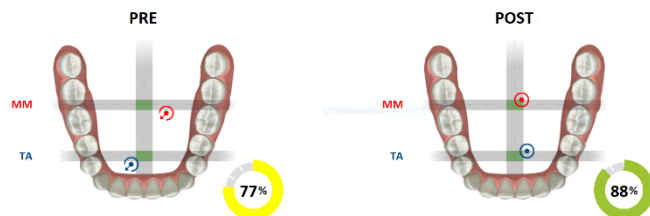Paz. 6, sesso femminile, 59 anni

MRI: Istituto medico radiologico di Zurigo (Stadelhofen)

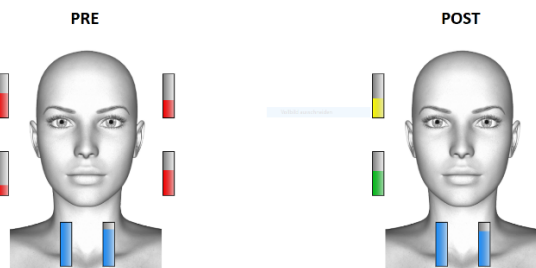
### TC del naso

Caratteristiche cliniche: cefalea mascellare e fronto-temporale, clinicamente non correlata. Sinusite? Come causa di mal di testa? Attualmente normale ventilazione dei seni paranasali e complesso osso-meato libero. Cisti da ritenzione mucosa dei seni mascellari su entrambi i lati. Deviazione del setto nasale a sinistra. Leggera artrosi dell'articolazione temporo-mandibolare su entrambi i lati con ipertrofia massetere a destra con accorciamento del ramo ascendente della mascella inferiore a destra (circa 10 mm).

EMG Teethan®, aumentando l'altezza dei denti a dx migliora la performance muscolare generale.



| Indizes | PRE      | POST     | Normaldaten |
|---------|----------|----------|-------------|
| POC TA  | 77.60% R | 78.10% L | 83≤(%)≤100  |
| POC MM  | 59.99% L | 87.17% L | 83≤(%)≤100  |
| BAR     | 86.22% A | 91.89% P | 90≤(%)≤100  |
| TORS    | 73.32% R | 91.44%   | 90≤(%)≤100  |
| IMP     | 52.12%   | 100.01%  | 85≤(%)≤115  |



| Indizes | PRE      | POST     | Normaldaten |
|---------|----------|----------|-------------|
| ASIM    | -10.06%  | -15.19%  | -10≤(%)≤10  |
| POC SCM | 85.34% R | 83.65% R | 83≤(%)≤100  |
| CL      | 6.62%    | 7.72%    | 0≤(%)≤15    |

